

Differential Diagnoses for the Cervico-Thoracic-Shoulder Region

Laurie Edge-Hughes, BScPT, MAnimSt, CAFCI, CCRT
The Canine Fitness Centre Ltd., Calgary, AB, Canada

Cervical spine

<i>Lesion</i>	<i>Clinical signs</i>	<i>Test</i>
Facet joint dysfunction	<ul style="list-style-type: none"> • Decreased active motion • May yelp or resist certain ranges of motion 	Joint glides -discomfort to test -asymmetric motion from side to side (stiffness) Tenderness on palpation
Disc lesion A) Herniation or extrusion	<ul style="list-style-type: none"> • May have neurologic signs, rear legs are affected first with spinal cord involvement • May have nerve root signature stance if lateralized • Positive for severe neck pain, (screaming in small dogs) • Head down posture • Neck muscle spasm/ guarding 	Joint glides -Much pain and resistance to glides, -animal may even collapse Severe tenderness on palpation
Disc lesion B) Degeneration C) Ligamentous hyperplasia D) Ligamentous hypermobility	<ul style="list-style-type: none"> • May have neurologic signs, rear legs are affected first • May have nerve root signature stance if lateralized • Positive for neck pain • Resistance to glides • Head down posture • Neck muscle spasm/ guarding 	Joint glides -stiffness and pain Often tenderness on palpation (but not always) - tenderness not as tender as the acute disc herniation/extrusion
Fibrocartilaginous embolism	<ul style="list-style-type: none"> • May have UMNL neurologic signs, affecting rear legs are first if the CORD is compromised • May have nerve root signature stance or LMNL signs if the dorsal horn &/or nerve roots are affected at that segmental level 	Joint glides - No stiffness No tenderness or minimal tenderness on palpation.
Neural impingement A)Osteophytes B)Nerve root foramen narrowing C)Facet OA D)Lateralized IVDD, DDD, FCE...	<ul style="list-style-type: none"> • May have lameness • May have nerve root signature stance or LMNL signs • Certain head movements or activities can result in lameness, root signature stance, yelping &/or PWB in stance 	Joint glides that 'close down' the affected side (extension of the facet joint) may cause pain, exacerbate lameness, cause immediate licking or chewing of the distal limb or cause a root signature stance. Nerve stretches may result in any/all s/s mentioned above May or may not have pain on palpation

Thoracic Spine and Ribs

<i>Lesion</i>	<i>Clinical signs</i>	<i>Test</i>
Dysfunction (facet joints or ribs)	<ul style="list-style-type: none"> • Subtle off-loading of limb(s) • Rib issues may show gross/ subtle lameness and pain on palpation • Lesions in the cranial thoracic spine and the 1st three ribs may mimic shoulder lameness 	Joint glides -restricted, painful, asymmetric motion Pain on palpation (mild to severe)
Disc lesion	<ul style="list-style-type: none"> • Can look like degenerative myelopathy, except for pain on deep palpation 	+PAIN on dorso-ventral pressures for facet joints – more so with lateral spinous process pressures Pain and spasm with deep palpation of epaxial muscles Pain on palpation of the adjacent ribs bilaterally. Pain with disc test

Shoulder

<i>Lesion</i>	<i>Clinical signs</i>	<i>Test</i>
Tendonopathies	<ul style="list-style-type: none"> • Commonly occur in biceps, supraspinatous and/or infraspinatous tendons • Lameness or off loading of a limb 	Tenderness on palpation Discomfort to stretch (Pain on resisted contraction)
Muscle strain / Myofascial Trigger points	<ul style="list-style-type: none"> • Commonly occurs in teres major, latissimus dorsi and/or long head of triceps 	Tenderness on palpation Discomfort to stretch
Medial instability (With involvement of medial glenohumeral ligaments and possibly the subscapularis tendon as well)	<ul style="list-style-type: none"> • Forelimb may be abducted and externally rotated • May show lameness • May suffer from other soft tissue shoulder injuries 	Excessive abduction Tenderness to palpate & stretch the subscapularis muscle Pain with end range extension ROM May have biceps tendon involvement
Hypermobility	<ul style="list-style-type: none"> • May show lameness • May show a head-bob/lameness when transitioning between walk & trot • May suffer from other soft tissue shoulder injuries 	Medial – Lateral glides Cranial - Caudal glides -hypermobility -may click/clunk with testing May have biceps tendon involvement
OCD/OA	<ul style="list-style-type: none"> • Lameness or stilted gait • OCD may show an on/off lameness or lameness just after a turn 	Joint glides -may be restricted or painful Pain on joint compressions without pain on distraction Range of motion -pain to fully flex and on end range extension May have biceps tendon involvement
Panosteitis and osteosarcoma	<ul style="list-style-type: none"> • Lameness 	Palpation with deep digital pressure to the affected portion of the humerus

THE CERVICAL SPINE

Signs and Symptoms of Cervical Spine Dysfunction

In humans, disorders of the upper cervical spine frequently result in headaches, and patients with neuromusculoskeletal disorders of the neck usually complain of pain as well as associated symptoms such as stiffness or dizziness. (Maitland et al 2005) It is also possible for patients to experience pain in the scapula, shoulder or arm. Disorders of the upper cervical spine (OA joint – C2/3) zygapophysial joints (facet joints) are often associated with suboccipital pain, whereas disorders of the lower cervical spine are generally related with suprascapular pain. (Maitland et al 2005) Animal owners may notice that their dog yelps with certain head movements, or avoids certain head positions or movements (i.e. turning, or bending down to the food or water bowl). The animal may exhibit a head down posture or simply just a change in attitude and disposition. The dog may avoid shaking its head and could even exhibit front leg lameness if there is a nerve root compression / impingement. As well, obsessive licking or chewing of the front limb along a spinal dermatome could also indicate a nerve root compression / impingement. Owners might also express that they think that their animal has a headache. While such an occurrence cannot be verified, it is certainly worth making a mental note about.

Anatomy

Zygapophysial Joints (Facet Joints) in the Canine Cervical Spine

Breit & Kunzel (2002) described four variations of caudal facet shapes in the canine cervical spine (C3 – C7); plane, concave, convex and sigmoid. There is an increased incidence of curved facets at the caudal cervical spine, with large male dogs being most prone to development of concave caudal articular surfaces. Convex and sigmoid facet shapes are an indication of axial rotation ability. The facet joints change shape from plane to curved within the first year of life, at some point after 8 weeks of age. This was taken to be a response to biomechanical stimuli acting on the immature facet joints. Generally, the cervical facet joints are oriented horizontally, which the authors claim to be consistent with a weight-bearing function.

A cervical rib, if present will articulate with the transverse process. In some cases, the true rib 1 will articulate with C7 and the fibrocartilage between C7 and T1.

Spinal Nerves of the Cervical Spine

Table 2.2. Segmental Nerve Roots, Peripheral Nerves and Thoracic Limb Muscle Innervation

Nerve	Nerve Roots	Muscles
Suprascapular N.	(C5), C6, C7	Supraspinatus, Infraspinatus
Subscapular N.	C6, C7	Subscapularis
Axillary N.	(C6), C7, C8	Teres Major, Teres Minor, Deltoideus, (Subscapularis)
Pectoral N.	C7, C8	Superficial and Deep Pectorals
Musculocutaneous N.	C6, C7, (C8)	Biceps Brachii, Brachialis, Coracobrachialis
Radial N.	C7, C8, T1, (T2)	Triceps brachii, Extensor carpi radialis, Ulnaris lateralis, Common digital extensor, Lateral digital extensor
Median N.	C8, T1, (T2)	Flexor carpi radialis, Superficial digital flexor, (Deep digital flexor)
Ulnar N.	C8, T1, (T2)	Flexor carpi ulnaris, Deep digital flexor
Thoracodorsal N.	(C7), C8, (T1)	Latissimus Dorsi

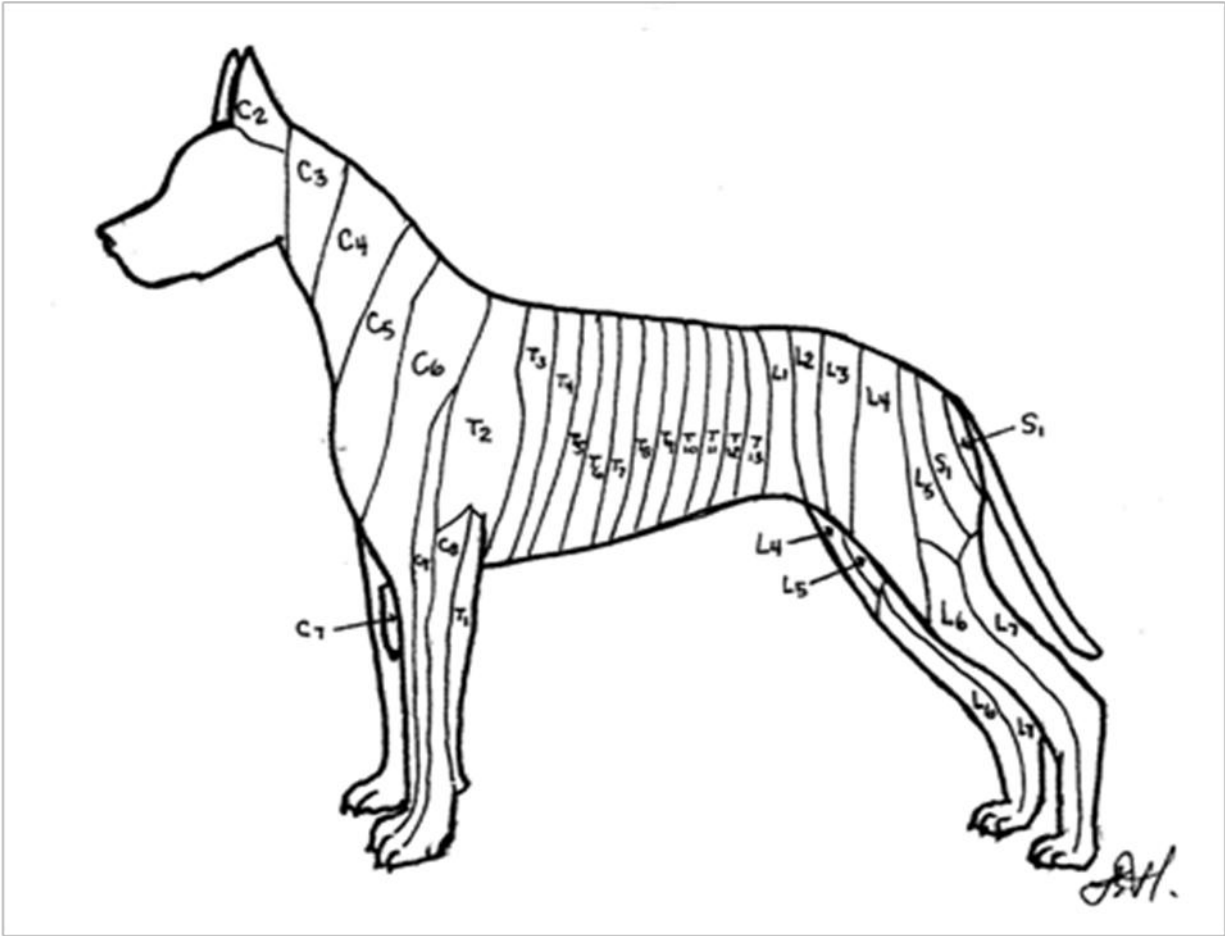


Figure 2.1 Dermatomes of the dog. (Adapted from Oliver et al 1987)

Caudal Cervical Spine Anatomy

- Bones
 - C2 – C6

C2 is easy to find, just behind C1, and C6 is easy to find with its large transverse process located on the ventrolateral aspect. C3 – C5 fit between these two more easily identifiable landmarks!

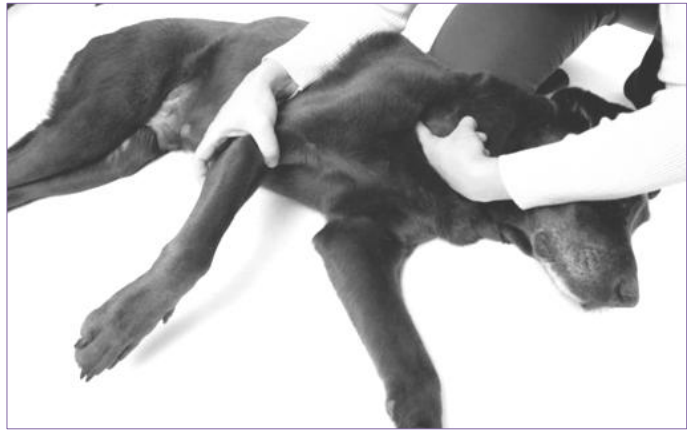

Ventrolateral aspect

Caudal Cervical Spine Anatomy

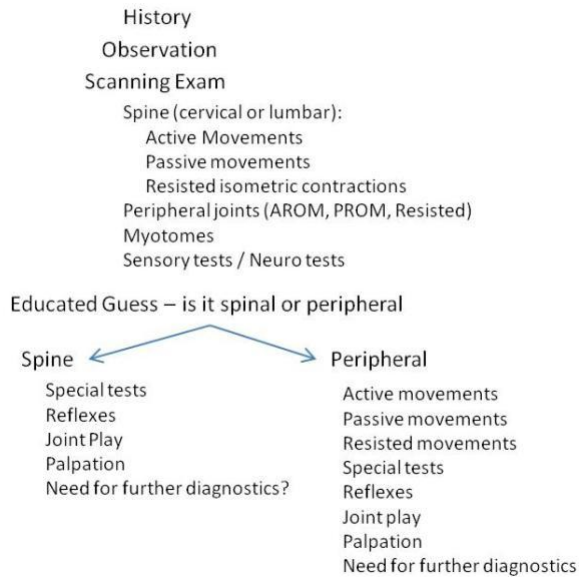
- **Bones**
 - C7

C7 is located MEDIAL to the scapula & glenohumeral joint. You will need to have the animal relaxed and/or turn the animal's head towards the side you are testing to take the tension out of the adjacent musculature



Assessment Algorithm

Scanning Exam Assessment



© Laurie Edge-Hughes 2011

This information is the property of L. Edge-Hughes and should not be copied or otherwise used without express written permission of the author.


Caudal Cervical Spine Assessment Techniques

- A Spinal Scan
 - Cookie stretches
 - The Cervical Spine
 - Extension




Caudal Cervical Spine Assessment Techniques

- A Spinal Scan
 - The Cervical Spine
 - Cookie stretches
 - Flexion




Caudal Cervical Spine Assessment Techniques

- A Spinal Scan
 - The Cervical Spine
 - Cookie stretches
 - Rotation



Caudal Cervical Spine Assessment Techniques

- A Spinal Scan
 - The Cervical Spine
 - Cookie stretches
 - Side bending



© Laurie Edge-Hughes 2011

This information is the property of L. Edge-Hughes and should not be copied or otherwise used without express written permission of the author.

Caudal Cervical Spine Assessment Techniques

NOTE: What is the END FEEL of the glide?

- Modified Cervical Side Glide



As you move down the spine, you will be side bending the dogs neck further and further towards the side you are testing.

Caudal Cervical Spine Assessment Techniques

- Side Glides with rotation:
 - Perform the side glide as above but this time pull your mobilizing hand dorsally to create an ipsilateral rotation side bend.
 - Move from C2 to C7.




Side glides with rotation

Caudal Cervical Spine Assessment Techniques

•Side Glides with extension or flexion:

- Perform the side glide as above but this time start with the dog's neck in a flexed or extended position.
- With the neck in extension, you are closing down the facet on the side from which you are performing the glide
- With the neck in flexion, you are opening the facet on the contralateral side to which you are performing the glide
- Move from C2 to C7.

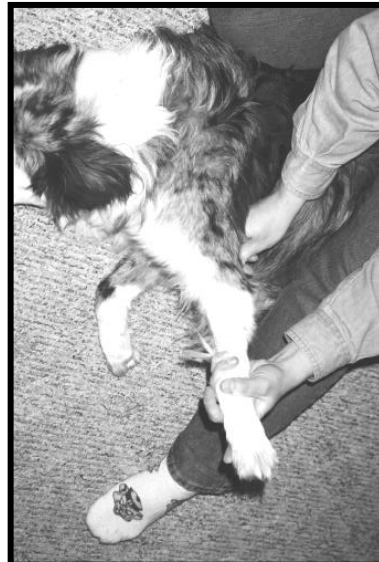

Caudal Cervical Spine Assessment Techniques

Adverse Neural Tissue Tension Testing

– The Median Nerve:

- In lateral recumbency
- Depress the scapula
- Abduct the shoulder
- Externally rotate the shoulder
- Straighten the elbow
- Extend the carpus



Caudal Cervical Spine Assessment Techniques

Adverse Neural Tissue Tension Testing

– The Radial nerve

- In lateral recumbency
- Depress the scapula
- Internally Rotate the shoulder
- Flex the shoulder
- Straighten the elbow
- Flex the carpus



Caudal Cervical Spine Assessment Techniques

Adverse Neural Tissue Tension Testing

– The Ulnar Nerve: (the sexy dog's nerve!)

- In lateral recumbency
- Depress the scapula
- Abduct the shoulder
- Flex the elbow
- Extend the carpus



© Laurie Edge-Hughes 2011

This information is the property of L. Edge-Hughes and should not be copied or otherwise used without express written permission of the author.

Caudal Cervical Spine Assessment Techniques

Adverse Neural Tissue Tension Testing

– The Musculocutaneous Nerve

- In lateral recumbency
- Depress the scapula
- Abduct the shoulder
- Internally Rotate the shoulder
- Extend the elbow



Caudal Cervical Spine Assessment Techniques

Consideration of Findings

- Does the animal exhibit a head-down posture or avoid any or certain movements of the head & neck?
- Is there abnormal tone of the cervical musculature?
 - Hypertonicity and muscle guarding?
- Is the dog exhibiting any upper motor neuron lesion signs or symptoms in the rear limbs or forelimbs?
- Is the dog exhibiting an lower motor neuron lesion signs or symptoms in the forelimbs?
 - Unilateral or bilateral?
- Is the animal lame?

© Laurie Edge-Hughes 2011

This information is the property of L. Edge-Hughes and should not be copied or otherwise used without express written permission of the author.

Consideration of Findings

- Was there tenderness on palpation of the cervical spine?
- Was there discomfort to testing side glides?
 - Mild discomfort or severe pain?
- Was there stiffness to testing side glides?
 - Was there a mobility restriction when comparing sides or vertebral segments cranially or caudally
 - Was the end feel normal?
- Did side glide testing exacerbate any 'LMNL' signs or symptoms?
 - Can these be correlated with unilateral 'closing' of a facet joint?
- Do any of the nerve stretches yield an increase in 'LMNL' signs or symptoms?

THE CRANIAL THORACIC SPINE

Signs and Symptoms of Thoracic Spinal Dysfunction

In humans, thoracic spine dysfunctions are associated with complaints of pressure headaches, aching at the back of the shoulders, over the pelvis, in the axilla or medial side of the elbow, heaviness and tiredness of the arms or legs, a glove distribution of symptoms, traumatic girdle pain, scapular / abdominal / kidney pains or indigestion, front limb/shoulder mobility restriction. (Maitland et al 2005; Hengeveld and Banks 2005) This author has witnessed dogs with dysfunctions of the thorax exhibiting and exaggerated kyphosis or lordosis of the thoracic region, discomfort to petting over the thoracic region, expression of pain with jumping or moving while in a recumbent position, wrestling with other dogs, forelimb lameness or limb favoring, head-down posturing, or a reduction in athleticism.

Anatomy

The cranial thoracic spine

In the cranial series of thoracic vertebrae (T1 – T9), the zygapophysial joints (facets) are approximately horizontal and overlap, whereas in the caudal thoracic and lumbar region, they are vertically aligned. (Breit 2002a) In the dog, this change usually occurs at the 10th thoracic vertebrae. In a study of the first to ninth thoracic vertebra, Breit 2002a found a 63% incidence of unilateral or bilateral aplasia of the zygapophysial joints exclusively in small dogs. Asymmetry in size between the left and right articular surface was a common feature in all sizes of dogs. She proposed that the alignment of the facets is associated with postnatal loading of the immature articular cartilage surfaces and is not congenitally determined and that biomechanical factors play a role in the development of facet aplasia. A restriction in motion may play a role in the development of this condition, indicating that the arches of adjacent vertebra do not touch. Weight bearing is suspected to be the main function of the zygapophysial joints in large dogs. The intervertebral disc may well compensate for the functional loss of zygapophysial joints in

© Laurie Edge-Hughes 2011

This information is the property of L. Edge-Hughes and should not be copied or otherwise used without express written permission of the author.

small dogs, however there was no evidence that aplasia of zygapophysial joints increases the risk of developing intervertebral disc disease (IVDD) or defomative spondylosis in small breeds. According to human literature, the orientation of the facet joints at the lower cervical spine and upper thoracic spine allows for some degree of lateral bending.(Singer 2004) Clinically, lateral bending at T1 to T6 is accompanied by rotation to the same side. Below T7, the direction of the conjunct motion is variable.(Lee 2003)

Rib articulations

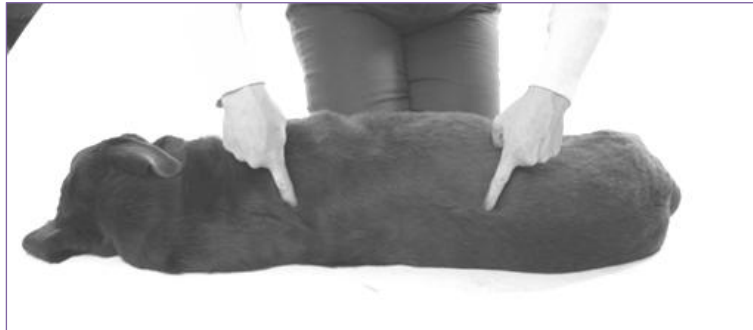Rib articulations (costal fovea) are located at the cranial and caudal sides of each thoracic vertebra T1 – T11 (called the cranial and caudal costal fovea or the demifacets). The rib head 1 articulate with T1 body and sometimes C7. It also articulates with the fibrocartilage between C7 and T1. The tubercles of the ribs articulate with the transverse processes of the thoracic spine at the same number as the rib. The body of T12 often lacks a caudal demifacet and T12 and T13 always have only one complete fovea on each side. (Evans 1993) The costovertebral joints and rib cage play an important role in providing stability to the thoracic spine.(Oda et al 1996) The articulation of the rib head, including the support of the radiate ligament, articular capsule, costotransverse ligament and intra-articular ligament, plays an important role in resisting rotations around the axes in lateral bending.(Takeuchi et al 1999) Hence the thoracic spine may be significantly less stable when the costovertebral joints are injured. It is useful to note that the shape of the costovertebral joints in dogs are similar to those in humans, and the range of motion (ROM) of the thoracic motion segments are not very different from those of humans.(Oda et al 1996, Takeuchi et al 1999)

The Cranial Thoracic Spine

- **Bones**
– T1 – T13

Note: T1 – T5/6 are the segments more likely to result in forelimb lameness or 'off loading'.

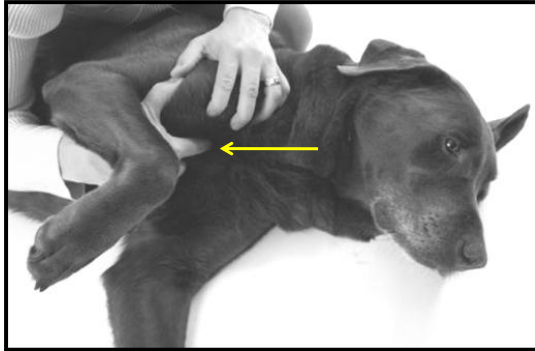Assess for pain & discomfort with direct dorso-ventral pressures



The Cranial Thoracic Spine

- **Bones**
 - Rib 1

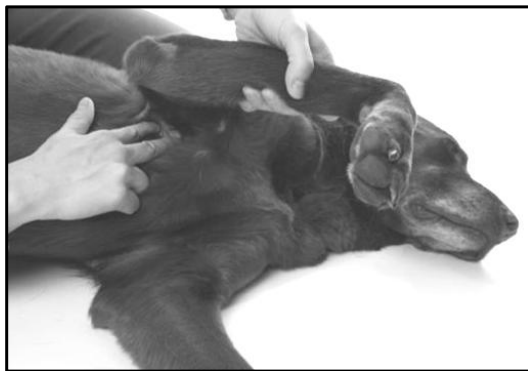Assess for pain & discomfort with a direct caudal pressure



The Cranial Thoracic Spine

- **Bones**
 - Ribs 2 & 3 under the scapula

Assess for pain & discomfort with a dorso-ventral pressure at the 'angle' of the rib.



Accessing ribs 2 - 5

The Cranial Thoracic Spine

- **Bones**
 - Sternum / Manubrium



Assess for pain & discomfort with a ventro-dorsal pressure

The Cranial Thoracic Spine

- **Side Glides**
 - Lift or push the dog's head in one direction while pushing the spinous process in the opposite direction as the motion.



© Laurie Edge-Hughes 2011

This information is the property of L. Edge-Hughes and should not be copied or otherwise used without express written permission of the author.

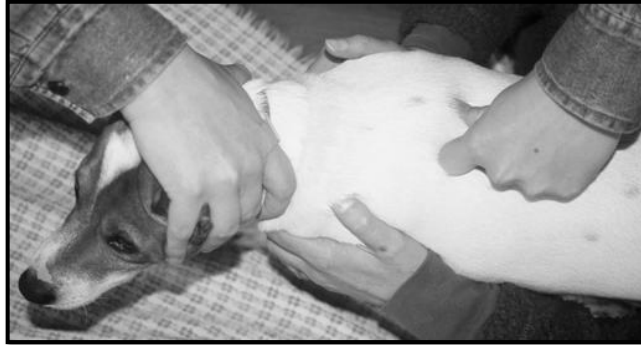The Cranial Thoracic Spine

• **Bilateral Dorso-ventral pressures**

–Use a thumb and index knuckle to do a P-A on the transverse processes / articular pillars simultaneously.

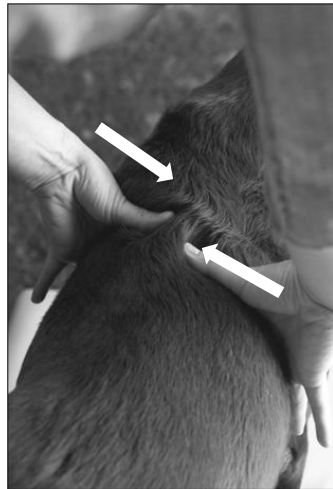
- This may give you information as to where along the thoracic spine there is stiffness (hypomobility).
- Be sure to support under the chest.
- Assess for quality and quantity of movement, end feel and pain.

–Angle slightly cranially above T9/10



The Cranial Thoracic Spine

• **Testing the Disc / Lateral Translation:**



- For segment T3/4 to T10/11 and segmental ribs. Compress one rib (i.e. left rib 6) (from the lateral side or dorsolateral side) and shear the contralateral rib just above (right rib 5) PURELY medially in the transverse plane.
- NORMALLY, there should be little/if any movement. The primary structure being tested is the disc!
- IF you are creative, you can still use this technique with the ribs under the scapulae as well!

The Cranial Thoracic Spine

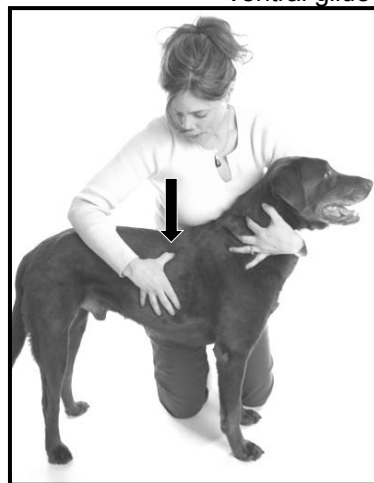Push downward from the top at the costovertebral junction. Pull up from below at the sternocostal junction or costochondral junction. Assess discomfort. Feel the end feel. Compare.

• Ribs

Dorsal glide



Ventral glide



THE SHOULDER

Anatomy

The shoulder joint is a ball and socket joint. The primary motion at this joint is that of flexion and extension; however it does have the ability to create the motions of rotation and abduction/adduction.

Ligaments of the shoulder are the medial and lateral glenohumeral ligaments (labiohumeral ligaments). They are essentially thickenings of the joint capsule. Additionally, the transverse humeral ligament runs across the origin of the biceps in the bicipital groove of the humerus. Most of the support for this joint is provided by the Biceps, Supraspinatus, Infraspinatus, Subscapularis, Teres Major, and Teres Minor, as well as compression of the joint during weight bearing. The canine shoulder joint does not typically possess a labrum.

Specific Canine Shoulder Injuries

Problems specific to the canine shoulder joint include tendinopathies of the supraspinatus, and subscapularis muscles, bicipital tenosynovitis or bursitis, medial shoulder ligamentous instability, and strains of the teres major muscle.

Supraspinatus calcification as well as tendinosis has been reported in veterinary literature.(Fransson et al 2005; Long & Nyland; Muir et al 1996; Laitinen & Flo 2000; Flo & Middleton 1990; Soslowsky et al 2000; Bardet 1998) Calcification has been reported to be a cause of unilateral forelimb lameness in dogs, with an incidence of 2.8 – 7% in all clinically lame dogs.(Long & Nyland 1999) The indicated treatment is surgical excision.(Muir et al 1996; Laitinen & Flo 2000) However, mineralization of the suspraspinatus tendon is a common finding in asymptomatic limbs, and while improvement in symptoms is reported following surgery, long term follow up reveals that supraspinatus tendon mineralization can recur within a 5 year post-

operative period.(Laitinen & Flo 2000; Flo & Middleton 1990) Tendonosis lesions of the supraspinatus tendon have been described in dogs and may precede or be associated with calcium deposits in the tendon.(Fransson et al 2005; Long & Nyland 1999) Additionally, it has been shown that overuse injuries of the supraspinatus can be induced in an animal model with a simulation of repetitive eccentric muscle activity created by running rats on a decline treadmill.(Soslowsky et al 2000)

The biceps tendon is a major stabilizer of the canine shoulder joint impacting cranial, medial and lateral translations of the humerus relative to the glenoid cavity.(Sidaway et al 2004) Bicipital tenosynovitis is a commonly reported pathology of the biceps tendon. (Gilley et al 2002; Long & Nyland 1999; Kramer et al 2001; Bruce et al 2000; Davidson et al 2000) Biceps tenosynovitis has been described as an inflammation of the biceps tendon or origin, its tendon sheath and the bicipital bursa within the intertubercular groove in the proximal humerus.(Davidson et al 2000) While inflammatory pathology of this tendon does exist, in some dogs, this disease may be the result of a degenerative process rather than an inflammatory process.(Gilley et al 2002) Other disease processes localized to the biceps tendon include but are not limited to calcification, osseous metaplasia, bone chip in the tendon sheath, and osteophyte formation in the intertubercular groove or supraglenoid tubercle.(Davidson et al 2000; Gilley et al 2002; Long & Nyland 1999; Kramer et al 2001) Clinical evaluation of the biceps tendon includes the biceps tendon test (positioning the forelimb into shoulder joint flexion with the elbow extended – essentially a stretch of the biceps tendon), pain on focal digital pressure applied directly to the biceps origin and/or intertubercular groove and the biceps retraction test.(Bruce et al 2000; Davidson et al 2000; Gilley et al 2002) As well a history of chronic and/or progressive weight bearing lameness that is worse after exercise and affecting active middle-aged or older medium to large breed dogs is common.(Bruce et al 2000; Gilley et al 2002; Davidson et al 2000) However, Bardet (1998) proposed that the biceps tendon test (stretching the biceps tendon) appears to be more of an indicator of generalized shoulder joint pain than a pathognomonic sign of biceps tendon disorders.

Shoulder instability appears to be a common cause of lameness in medium and large-breed hyperactive dogs with a chronic permanent or intermittent foreleg lameness.(Bardet 1998) Other clinical signs of shoulder subluxation include atrophy of the shoulder muscles, non-weight-bearing lameness, spontaneous cries, signs and symptoms of disc disease or a ‘wobblers walk’ presentation, as well, abnormal craniocaudal or mediolateral translations (drawer tests) are reported to be consistent indicators of shoulder joint instability in dogs subsequently diagnosed by arthroscopic evaluation.(Bardet 1998) This same author suggested grading of the direction and degree of the drawer translation: Grade 1 – when the translocation of the head of the humerus on the glenohumeral joint is not appreciated; Grade 2 (Mild) – when the translocation is appreciated but is not enough to allow the head of the humerus to rise up on the rim of the glenoid cavity; Grade 3 (Moderate) – when the head of the humerus is appreciated but is not enough to allow the head of the humerus to rise up on the rim of the glenoid cavity; Grade 4 (Severe) – when the head of the humerus courses over the rim of the glenoid cavity and is dislocated. Additional clinical findings may include pain with the biceps tendon test and pain on shoulder joint hyperextension.(Bardet 1998) Cook et al (2005a) described clinical diagnostic testing utilizing measurement of shoulder abduction angles. In dogs diagnosed with instability, the mean abduction angles ($53.7 \pm 4.7^\circ$ measured goniometrically) were significantly larger than for all unaffected shoulders ($32.6 \pm 2.0^\circ$ measured goniometrically). They proposed that the difference between angles is substantial enough to suggest that a visual observation of this asymmetry may be all that is required to make a preoperative diagnosis of medial shoulder joint instability in dogs. Medial shoulder instability is attributable to pathology of the medial aspect of the joint capsule, the subscapularis tendon and or the medial glenohumeral ligaments and may

© Laurie Edge-Hughes 2011

This information is the property of L. Edge-Hughes and should not be copied or otherwise used without express written permission of the author.

precede glenoid cartilage or humeral head cartilage wear or defects and eventual degenerative joint disease.(Bardet 1998; Cook et al 2005a)

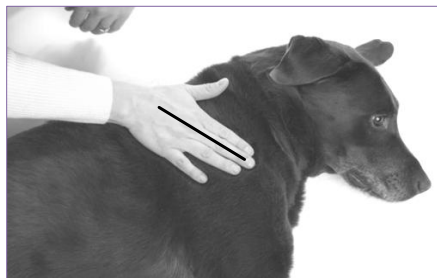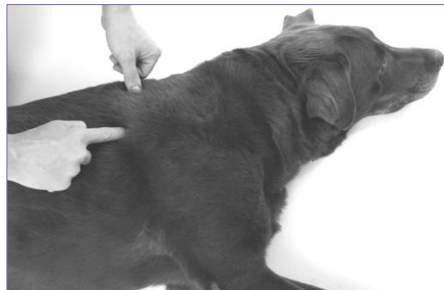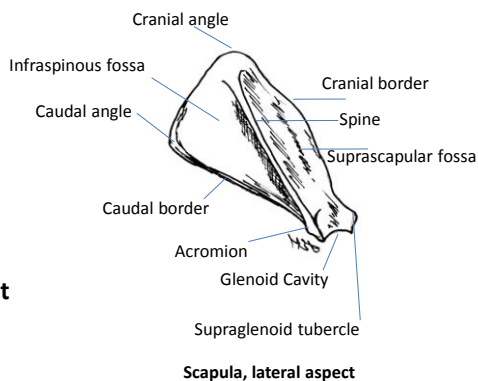
The teres major muscle originates from the caudal angle and caudal edge of the scapula and inserts into the eminence on the proximal 1/3 of the medial surface of the humerus and shares a common tendon of insertion with the latissimus dorsi.(Evans 1993) The teres major muscle is reported to flex the shoulder joint, however in analyzing the origin and insertion of teres major in the canine, this muscle can not only flex the shoulder but should also adduct and internally rotate the shoulder when the front limb is in an outstretched position.(Edge-Hughes 2004b) The proposed mechanism of injury would be an exaggerated extension, abduction and external rotation which could occur when a dog is running at high speeds and makes a sudden turn.(Edge-Hughes 2004b) Clinical presentation is of acute or chronic forelimb lameness that improves with rest but returns when allowed to resume normal activities.(Edge-Hughes 2004a) Physical examination reveals mild discomfort with full shoulder extension, inclusive of scapulothoracic movement, an increase in discomfort with the addition of abduction and external rotation, and moderate to severe tenderness (patient yelp or muscle twitching) on palpation of the teres major muscle or its tendon of insertion located in the ‘roof’ of the caudal aspect of the axilla.(Edge-Hughes 2004a)

The Glenohumeral Joint

- Palpation

- Scapula:

- Cranial angle
 - Caudal angle
 - **Teres Major attachment**
 - Spine
 - Acromion



The Glenohumeral Joint

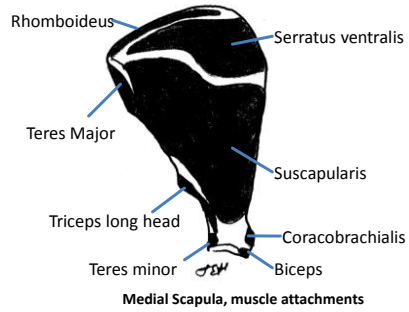
• Palpation

– Scapula

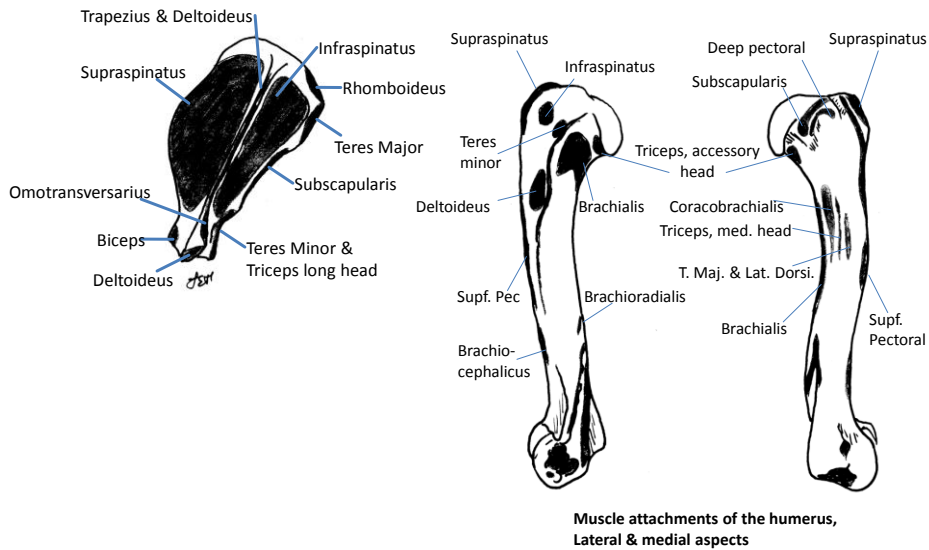
- Supraglenoid tubercle
- Same level as the acromion, on the medial side
- Attachment of biceps brachii

– Medial joint line

- Subscapularis crosses the medial joint line



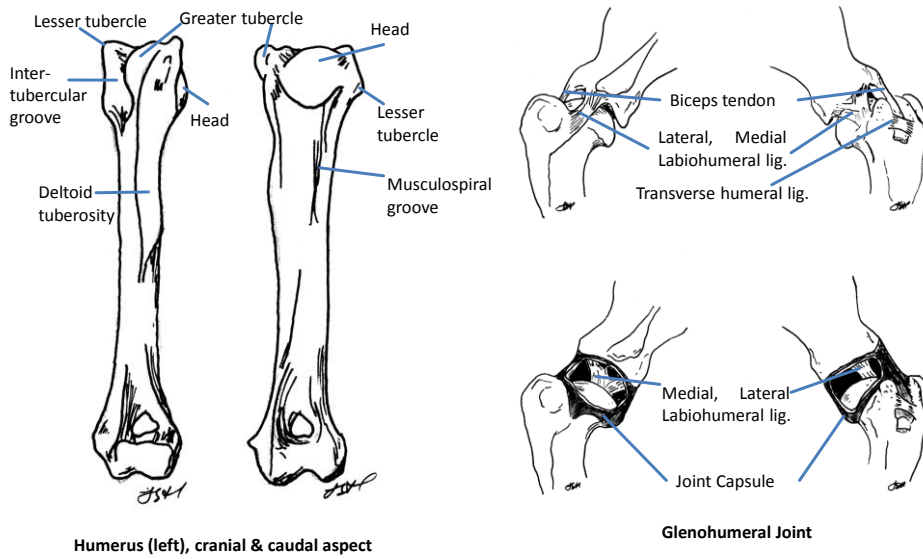
The Glenohumeral Joint



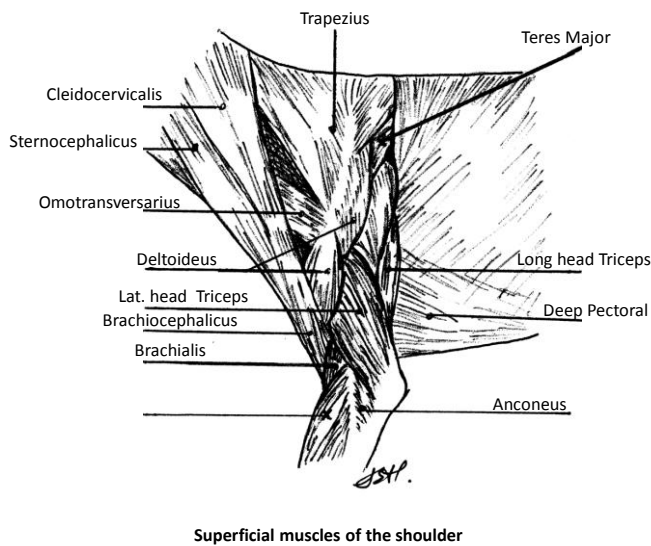
© Laurie Edge-Hughes 2011

This information is the property of L. Edge-Hughes and should not be copied or otherwise used without express written permission of the author.

The Glenohumeral Joint



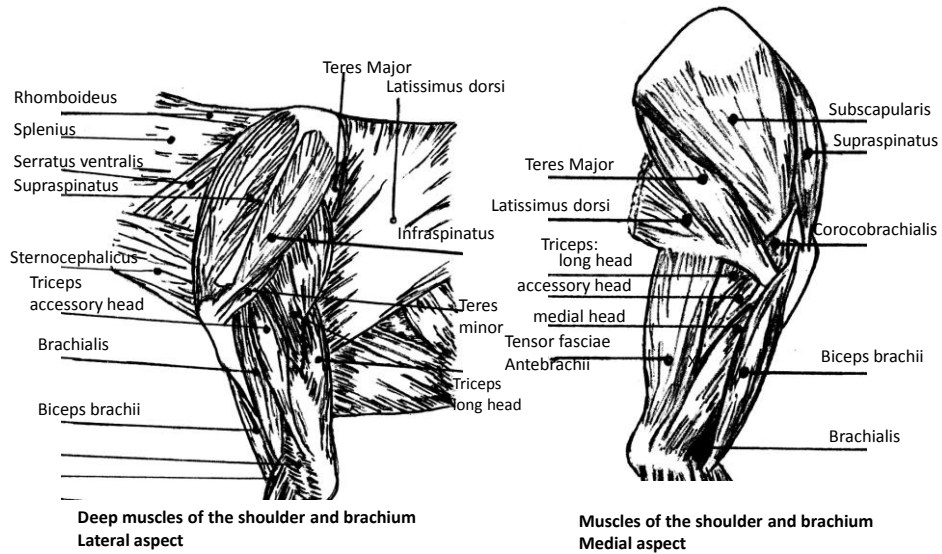
The Glenohumeral Joint



© Laurie Edge-Hughes 2011

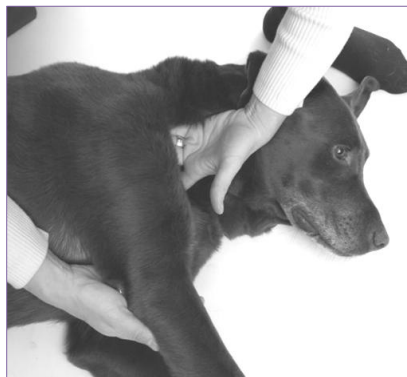This information is the property of L. Edge-Hughes and should not be copied or otherwise used without express written permission of the author.

The Glenohumeral Joint



The Glenohumeral Joint

- Palpate tendons – Medial to lateral...
 - Subscapularis:
 - Find the medial joint line...by default you are on the subscapularis tendon



© Laurie Edge-Hughes 2011

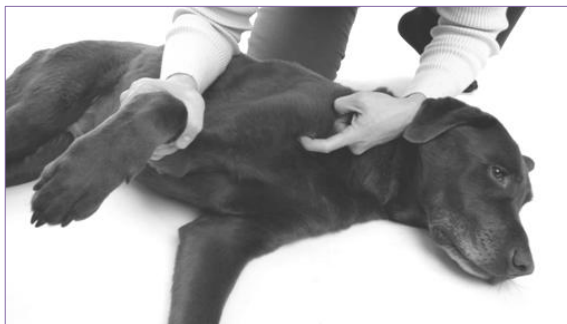This information is the property of L. Edge-Hughes and should not be copied or otherwise used without express written permission of the author.

The Glenohumeral Joint

- **Palpate tendons – Medial to lateral...**

- Biceps tendon (proximal):

- Find the intertubercular groove and begin to strum across the fibres.
 - ‘Strum’ proximally to the supraglenoid tubercle
 - ‘Strum’ distally to the musculotendinous junction



The Glenohumeral Joint

- **Palpate tendons**

- Supraspinatus:

- Find the greater tuberosity, move your finger dorsally to find the supraspinatus tendon and ‘strum’ across the fibres until you find the musculotendinous junction
 - It is a thick, sturdy tendon
 - The musculotendinous junction is higher (more dorsal) than the joint line... and this is where you NEED to palpate

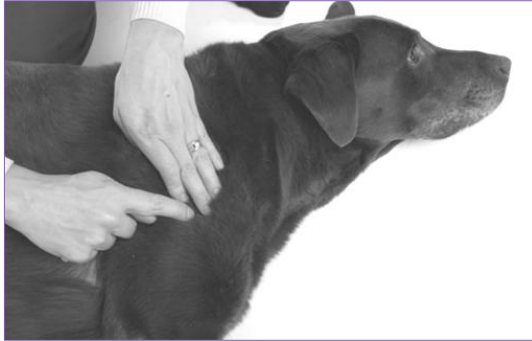

The Glenohumeral Joint

- Palpate tendons

- Infraspinatus:

- Find the acromion and ‘fall off’ of it caudally & distally. Strum for the tendon here. Make note that you will only palpate the most caudal aspect of the tendon
 - If you feel something meaty & squishy, it is deltoideus



The Glenohumeral Joint

- Palpate Muscles

- Long Head of triceps



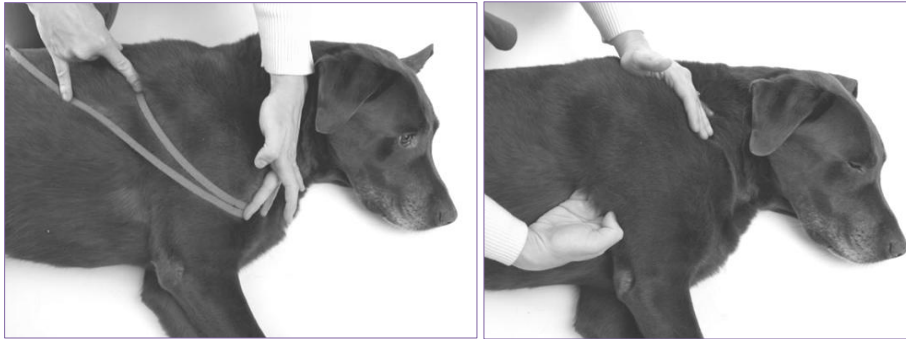Palpate for tenderness and feel for trigger points

© Laurie Edge-Hughes 2011

This information is the property of L. Edge-Hughes and should not be copied or otherwise used without express written permission of the author.

The Glenohumeral Joint

- Palpate muscles (caudo-medial)
 - Teres Major
 - Latissimus Dorsi



The Glenohumeral Joint

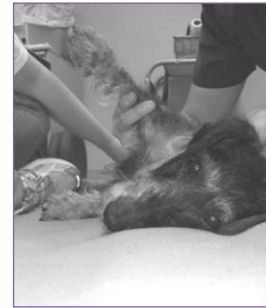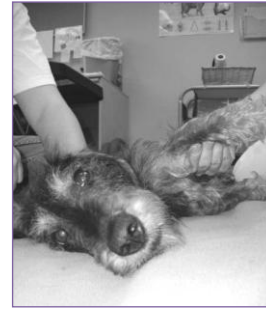- Range of Motion:
 - Note range, end feel, quality of movement, & discomfort
 - Extension (forwards) to 170 degrees
 - Feel for PURE glenohumeral range (stabilize the scapula)
 - Flexion (backwards) to 30 – 40 degrees
 - Medial Rotation to 40 – 50 degrees
 - Lateral Rotation to 40 – 50 degrees
 - Abduction to 32.6 ± 2.0 degrees
 - Test in extension!
 - Adduction to 40 – 50 degrees (???)

© Laurie Edge-Hughes 2011

This information is the property of L. Edge-Hughes and should not be copied or otherwise used without express written permission of the author.

The Glenohumeral Joint


- ROM & Stretching
 - Shoulder abduction
 - Medial shoulder instability evaluation / subscapularis stretch (one version)



Hypermobile

The Glenohumeral Joint

- Stretches
 - Supraspinatus: Flex the shoulder (plus or minus some internal rotation)
 - Biceps: Extend the elbow joint, and then add shoulder flexion.



The Glenohumeral Joint

- Stretches

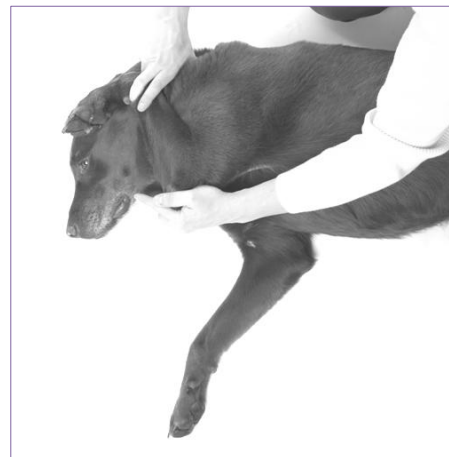
- Latissimus Dorsi & Teres Major: Extend the shoulder and add external rotation & abduction



The Glenohumeral Joint

- Stretches

- Long head of Triceps: Bend the elbow and extend the shoulder



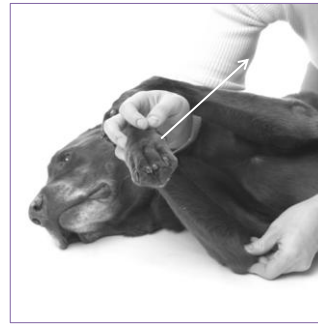© Laurie Edge-Hughes 2011

This information is the property of L. Edge-Hughes and should not be copied or otherwise used without express written permission of the author.

The Glenohumeral Joint

- Stretches

- Infraspinatus: Internally rotate & adduct the shoulder joint.



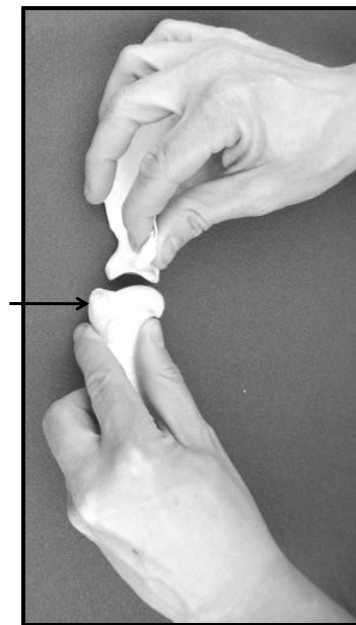
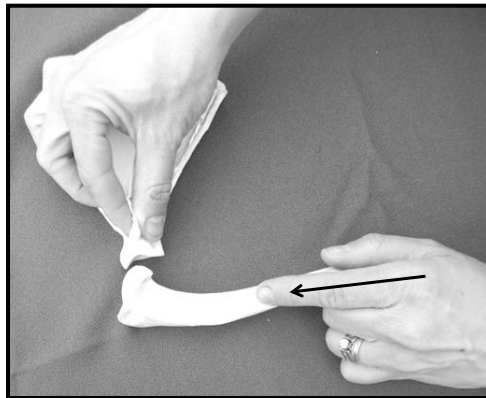
- Subscapularis: External rotation and add some abduction



The Glenohumeral Joint

- Joint Glides

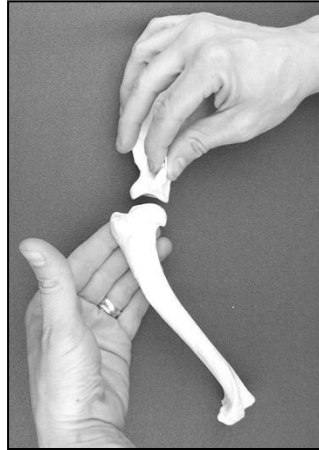
- Cranial & Caudal glides of the humeral head



The Glenohumeral Joint

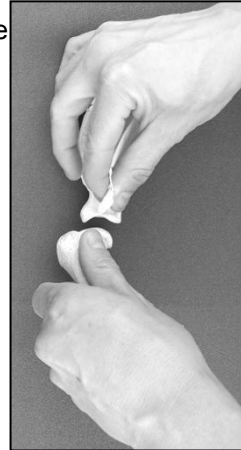- Joint Glides

– Medial & Lateral glides of the humeral head



Lift – lateral glide

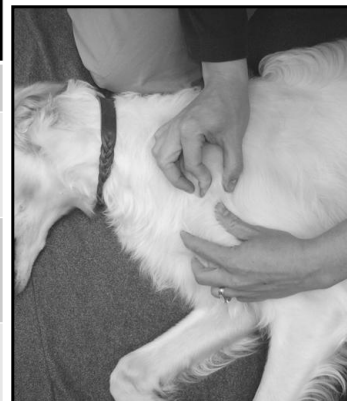Push – medial glide



The Glenohumeral Joint

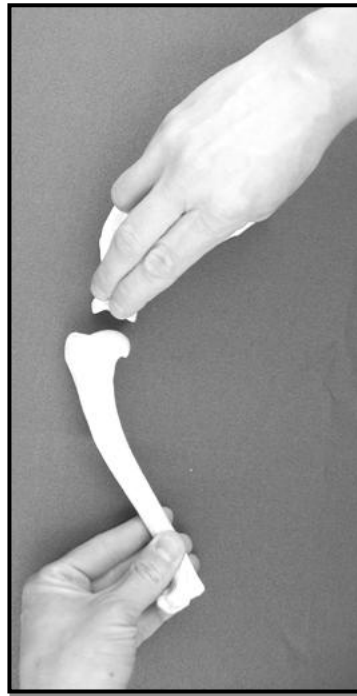
- SHOULDER INSTABILITY

Shoulder Drawer (aka translations or joint glides) Bardet 1998	
Grade 1	No appreciable translocation
Grade 2	Mild appreciable translocation, but no rise of the humeral head beyond the glenoid rim
Grade 3	Moderate appreciable translocation, but no rise of the humeral head beyond the glenoid rim
Grade 4	Severe translocation where-by the head of the humerus can course over the glenoid rim



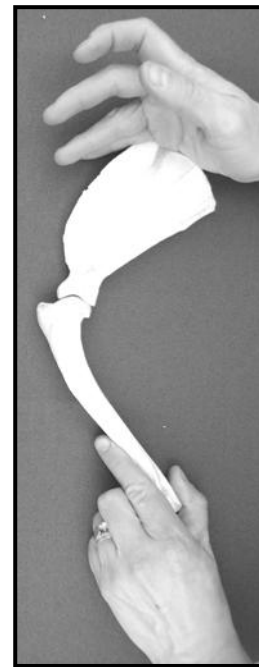
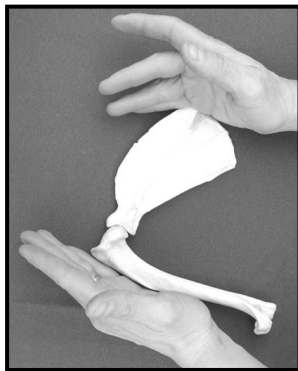
The Glenohumeral Joint

- Joint Glides
 - Joint distraction



The Glenohumeral Joint

- Joint Glides
 - Compressions in various ROM
 - In flexion if suspecting OCD lesion
 - Throughout range is suspecting joint OA

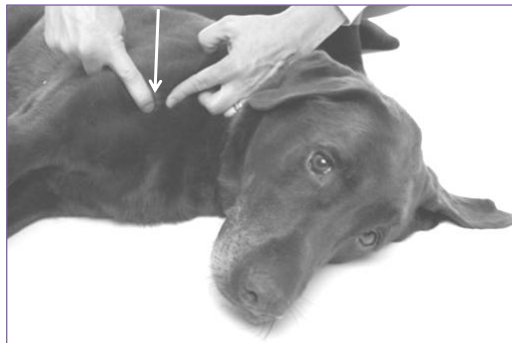

The Glenohumeral Joint

- **Joint Glides**
 - Scapular glides against the rib cage
 - Retraction & Protraction
 - Stretching of soft tissues (i.e. rhomboideus)

The Glenohumeral Joint

- **BONUS test**
 - Deep palpation of the humerus
 - (for Panosteitis – young dog – shaft of humerus)
 - (for Osteosarcoma – old dog – proximal humerus)



© Laurie Edge-Hughes 2011

This information is the property of L. Edge-Hughes and should not be copied or otherwise used without express written permission of the author.